

Interim Results From the Muenster Postmarket All-Comers Registry

A look at the latest data on use of the Eluvia drug-eluting stent in challenging SFA lesions.

BY THEODOSIOS BISDAS, MD, PhD



The atherosclerotic superficial femoral artery (SFA) remains one of the best investigated vascular territories in the human body. However, the vessel's characteristics and its exposure to external forces, especially near the knee joint, compromise the effectiveness of the currently available treatment strategies.¹ Traditional plain balloon angioplasty has shown a high restenosis rate (up to 60% at 12 months), and it cannot be further legitimized as standalone therapy for treating the SFA.² Similarly, the midterm outcomes of bare-metal stents did not confirm the initial enthusiasm for this approach due to considerably low patency rates, especially in long lesions.³

The introduction of drug-coated balloons (DCBs) with the concept of paclitaxel delivery into the arterial wall led to an effective prevention of intimal hyperplasia and restenosis.² However, the pharmacokinetic effect is highly variable between devices, which may influence the durability of this strategy. Still, any effort to leave nothing behind remains the recommended first-line approach in the SFA.

Nonetheless, two issues continue to limit the applicability of this strategy: (1) the lower penetration rate of paclitaxel through calcified lesions (severely calcified lesions are a barrier for the delivery of paclitaxel into the adventitial layer) and (2) the increased need of bailout stenting in chronic total occlusions and long lesions (> 15 cm). Fanelli et al confirmed the lower patency rate of DCB angioplasty in areas with a greater calcium burden.⁴ In such cases, removal of the calcium by atherectomy or the use of primary stenting to address recoil remain mandatory.⁵ In addition, DCB registries, which included all-comers and more challenging lesions, revealed a higher bailout stenting rate (up to 50%) when the length and severity of the lesions were greater.⁶ It should be noted that all randomized controlled trials studying DCBs have excluded patients with suboptimal

angioplasty, and thus the true rate of bailout stenting in these trials is unclear. Hence, the question is: if the approach of leaving nothing behind is not feasible, which is the best device to leave in the SFA?

DRUG-COATED STENTS

Based on the currently available evidence, drug-coated stents (eg, Zilver PTX, Cook Medical) are a good alternative to leave behind.⁷ Drug-coated stents combine the antiproliferative role of paclitaxel and the mechanical support of a bare-metal stent, with the drug directly coating the stent metal. Drug-coated stents showed promising long-term outcomes in short lesions,⁷ but a high restenosis rate in real-world and more challenging lesions.⁸ A possible explanation for this finding is that the release of the drug with drug-coated stents is completed within 1 month, while it is well known that the peak time of restenosis in the SFA reaches 12 months.⁹

Eluvia Stent

In contrast to drug-coated stents, the Eluvia stent (Boston Scientific Corporation) is the first drug-eluting stent that aims to follow the course of SFA restenosis and to increase vessel patency with controlled and prolonged release of paclitaxel for more than 12 months. The unique technology of the stent includes a dual-layer coating, which utilizes a primer n-butyl methacrylate (PBMA) layer that promotes adhesion of an active layer of paclitaxel and polyvinylidene fluoride-hexafluoropropylene (PVDF-HFP) onto the stent.¹⁰ This combination enables controlled and sustained elution of the drug over time. PBMA+ PVDF-HFP is a biocompatible and stable polymer that is currently used in the coronary everolimus-eluting stents (Xience V, Abbott Vascular; Promus, Boston Scientific Corporation), with well-established and proven safety and effectiveness results.

In regard to the stent design, the Eluvia stent is built on Boston Scientific's commercially available Innova self-expanding nitinol stent platform. A 6-F, low-profile, triaxial delivery system enables easy and accurate stent implantation. The stent architecture combines a closed-cell design at each end of the stent for precise deployment and an open-cell design for increased flexibility and fracture resistance.

Eluvia Versus Zilver PTX

The Eluvia stent is designed to provide the following advantages compared to the Zilver PTX stent:

- It includes a unique technology of drug-elution that sustains drug release in order to match the restenotic process in the SFA.
- The polymer is highly biocompatible with proven clinical safety.
- The Eluvia stent is built on the Innova stent platform, which was designed for the SFA with greater strength, flexibility, and fracture resistance.

However, the head-to-head comparison between drug-coated and drug-eluting stents in the framework of the prospective randomized controlled IMPERIAL trial will highlight the impact of polymer and will confirm or disprove the aforementioned advantages.

MAJESTIC TRIAL

At present, the effectiveness of the new concept and the safety of the Eluvia stent in humans are being studied in the prospective, core lab–adjudicated MAJESTIC trial.¹¹ In this multicenter, single-arm study, 57 patients (Rutherford category 2–4) underwent implantation of the Eluvia DES at 14 vascular centers. The mean lesion length was 71 ± 28 mm, with involvement of the distal SFA and proximal popliteal artery in 86% of the patients. Of note, 65% of the lesions were determined by the core lab to be severely calcified, and 46% of the lesions were total occlusions. Freedom from target lesion revascularization (TLR) at 2 and 3 years was 93% and 85%, respectively. Moreover, no stent fractures were reported, and clinical improvement was observed in 91% of the patients at 2 years.

PRELIMINARY RESULTS OF THE MUENSTER POSTMARKET REGISTRY

The MAJESTIC trial demonstrated the efficacy of the stent in relatively short lesions, but the performance of the device in real-world patients has not yet been investigated. For this reason, we analyzed our prospectively collected data between March 2016 (when the stent first became available

TABLE 1. PATIENT SYMPTOMATOLOGY AND LESION CHARACTERISTICS IN THE MUENSTER POSTMARKET REGISTRY

CHARACTERISTICS	NO. OF PATIENTS
Symptoms	
Rutherford stage 3	32 (52%)
Rutherford stage 4	14 (23%)
Rutherford stage 5	10 (16%)
Rutherford stage 6	6 (10%)
Lesion	
Mean length (in mm)	199 ± 107
Minimum lumen diameter (mean, in mm)	0.06 ± 0.17
Occlusion	49 (79%)
Moderate/severe Ca ²⁺	26 (42%)
Location	
Proximal SFA	33 (53%)
Middle SFA	43 (69%)
Distal SFA	47 (76%)
P1 segment	27 (44%)
P2 segment	2 (3%)
Run-Off Status	
0 vessels	1 (2%)
1 vessel	11 (18%)
≥ 2 vessels	50 (80%)

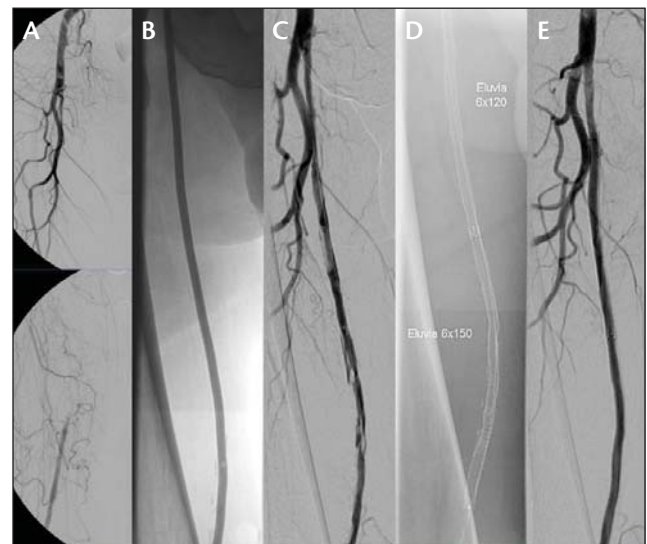


Figure 1. Case presentation of an occlusion of the right SFA (26 cm) in a man with Rutherford stage 5 disease (A). Predilatation with a 5-X 250-mm balloon catheter resulted in a flow-limiting dissection across the SFA (B, C). Implantation of two Eluvia stents (6 X 150 mm and 6 X 120 mm) (D) and completion angiography (E).

on the market) and April 2017. The study was a single-center, single-arm study that included 62 consecutive patients (39 men, 23 diabetics) undergoing implantation of the Eluvia stent. The indication for stent implantation was any subop-

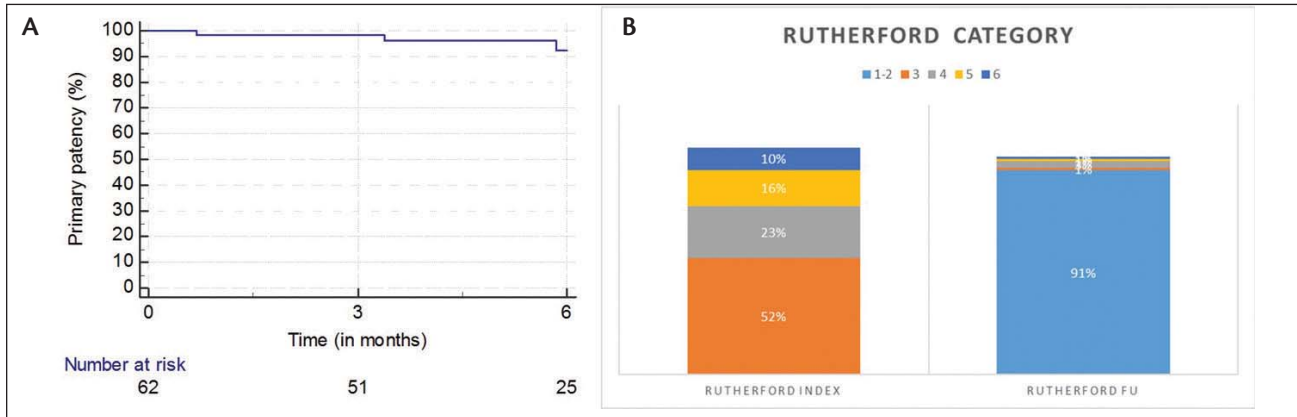


Figure 2. Primary patency at 6 months (A) and improvement of Rutherford clinical category at index and at 6 months follow-up in the Muenster postmarket registry (B).

timal angioplasty (flow-limiting dissection or recoil > 50%) after plain balloon angioplasty in 1 cm less than the nominal vessel diameter (Figure 1). Patients with in-stent or bypass stenosis, as well as those with acute limb ischemia (< 4 weeks), were excluded from this study. All patients underwent clinical examination and duplex ultrasound at 6 months, with repeat assessments planned at 12 months.

The primary endpoint of the study was primary patency, defined as freedom from significant restenosis (peak systolic velocity ratio > 2) or occlusion without any reintervention based on duplex ultrasound evaluation. A total of 104 stents were implanted in 62 patients. Table 1 provides the symptomatology of the patients and relevant angiographic characteristics of the included lesions. The average lesion length was nearly 20 cm, 79% of the lesions were total occlusions, and 42% of the lesions were severely calcified. The preliminary results showed a primary patency rate of 93% at 6 months (Figure 2), and 91% of the patients returned to Rutherford stages 1 or 2. Three occlusions were observed. No stent fractures were found on x-ray at 6 months. Secondary patency at 6 months was 96% (number at risk, 25), and freedom from TLR was 93% (number at risk, 28). Two patients, one with severe Rutherford stage 6 disease and a skin infection and another with Rutherford stage 6 disease and a traumatic injury underwent major amputations despite having patent stents.

CONCLUSION

Despite the efforts to leave nothing behind after endovascular treatment of the SFA, there is still a considerable

number of lesions that require bailout stenting. Due to the proven efficacy of paclitaxel, use of the Eluvia stent could be the most effective solution for treating the SFA. In this context, the first test of the Eluvia stent in our all-comers registry, and with the very challenging nature of SFA lesions, showed encouraging 6-month performance. ■

1. Stavroulakis K, Torsello G, Manal A, et al. Results of primary stent therapy for femoropopliteal peripheral arterial disease at 7 years. *J Vasc Surg.* 2016;64:1696-1702.
2. Laird JR, Schneider PA, Tepe G, et al. Durability of treatment effect using a drug-coated balloon for femoropopliteal lesions: 24-month results of IN.PACT SFA. *J Am Coll Cardiol.* 2015;66:2329-2338.
3. Bosiers M, Deloose K, Callaert J, et al. Results of the Protégé EverFlex 200-mm-long nitinol stent (ev3) in TASC C and D femoropopliteal lesions. *J Vasc Surg.* 2011;54:1042-1050.
4. Fanelli F, Cannavale A, Gazzetti M, et al. Calcium burden assessment and impact on drug-eluting balloons in peripheral arterial disease. *Cardiovasc Intervent Radiol.* 2014;37:898-907.
5. Stavroulakis K, Schwandt A, Torsello G, et al. Directional atherectomy with antirestenotic therapy vs drug-coated balloon angioplasty alone for isolated popliteal artery lesions. *J Endovasc Ther.* 2017;24:181-188.
6. Laird JR, Armstrong EJ. An overview of superficial femoral artery stenting. *Endovascular Today.* 2014;13(suppl):9-11.
7. Dake MD, Ansel GM, Jaff MR, et al. Durable clinical effectiveness with paclitaxel-eluting stents in the femoropopliteal artery: 5-year results of the Zilver PTX randomized trial. *Circulation.* 2016;133:1472-1483.
8. Iida O, Takahara M, Soga Y, et al. 1-year results of the ZEPHYR Registry (Zilver PTX for the femoral artery and proximal popliteal artery): predictors of restenosis. *JACC Cardiovasc Interv.* 2015;8:1105-1112.
9. Iida O, Uematsu M, Soga Y, et al. Timing of the restenosis following nitinol stenting in the superficial femoral artery and the factors associated with early and late restenoses. *Catheter Cardiovasc Interv.* 2011;78:611-617.
10. Gasior P, Cheng Y, Valencia AF, et al. Impact of fluoropolymer-based paclitaxel delivery on neointimal proliferation and vascular healing: a comparative peripheral drug-eluting stent study in the familial hypercholesterolemic swine model of femoral restenosis. *Circ Cardiovasc Interv.* 2017;10:e004450.
11. Müller-Hülsbeck S, Keirse K, Zeller T, et al. Twelve-month results from the MAJESTIC trial of the Eluvia paclitaxel-eluting stent for treatment of obstructive femoropopliteal disease. *J Endovasc Ther.* 2016;23:701-707.

Theodosios Bisdas, MD, PhD

Clinic for Vascular Surgery
St. Franziskus Hospital GmbH
Muenster, Germany
th.bisdas@gmail.com

Disclosures: Consultant to and receives speaker fees from Boston Scientific Corporation and Cook Medical.